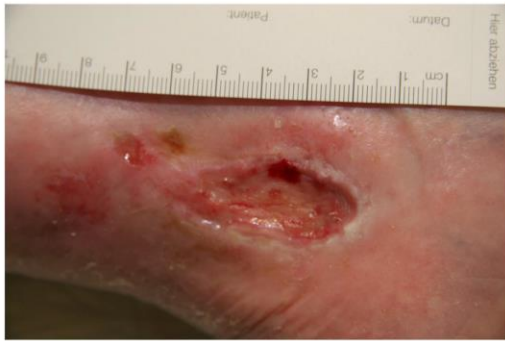


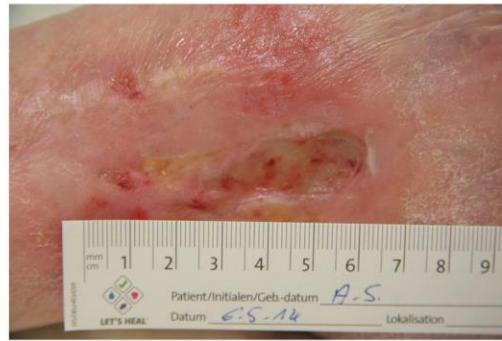
This patient is a 93 year old woman whose wound had never healed in 40 years despite the best efforts of German doctors. She was sent to Dr Busch and with his CellSonic he healed the wound with one treatment and the wound stayed closed.

**Patient 5; venös; 93J; weiblich; 600 Schüsse Level 4;
Z.n. Thrombose; Ulzera an dieser Stelle seit ca. 40 Jahren**

Vor Behandlung



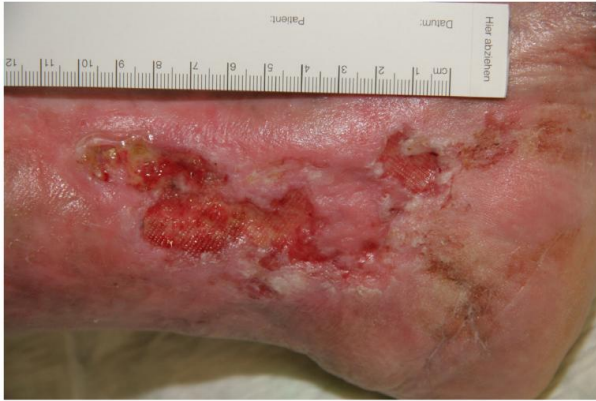1. Behandlung



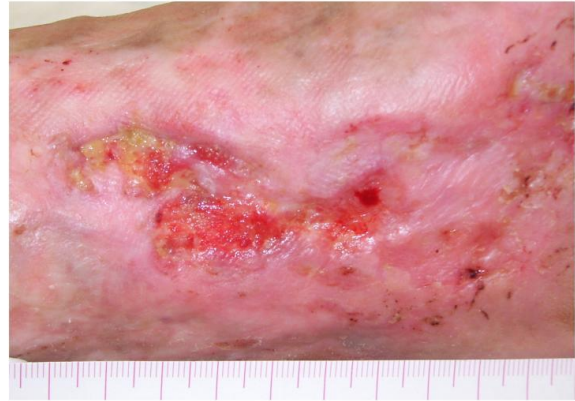This patient is an 81 year old woman whose wound had stayed open for 50 years. With CellSonic, Dr Busch healed the wound in 6 treatments and it stayed closed thereafter.

**Patient 14; venös; 81J; weiblich; 1800 Schüsse;
Ulcer seit ca. 50 Jahren**

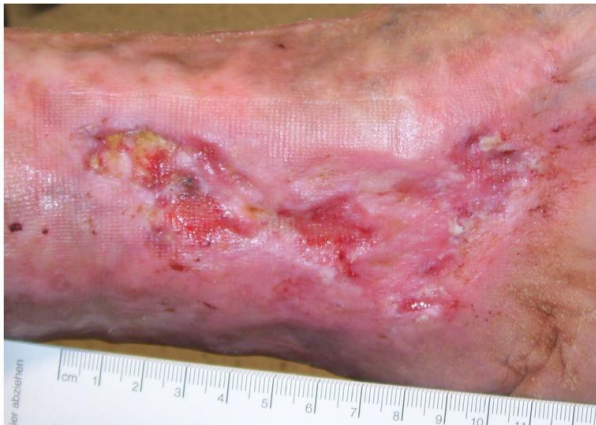Vor Behandlung



1. Behandlung



2. Behandlung



3. Behandlung

